

HOSTED BY



Contents lists available at ScienceDirect

Journal of King Saud University – Science

journal homepage: www.sciencedirect.com

Original article

Dandelion (*Taraxacum officinale*) seeds extract attenuates hypercholesterolemia in swiss albino mice

Doaa Mohamed El-Nagar*, Badr Abdullah Al-Dahmash, Saad Alkahtani, Areej Ahmed Kalu, Ahmed Rady

Zoology Department, College of Science, King Saud University, P.O. Box 2455, Riyadh 11451, Kingdom of Saudi Arabia



ARTICLE INFO

Article history:

Received 24 October 2021

Revised 27 May 2022

Accepted 19 June 2022

Available online 26 June 2022

Keywords:

Hypercholesterolemia

Dandelion

Steatosis

Inflammation

ABSTRACT

Objectives: The present search aimed to investigate the effect of dandelion seeds extract to reduce hypercholesterolemia and its hazardous effects on liver.

Methods: Forty male albino mice were divided into 4 groups, 10 mice per each, the first was the untreated control, the second treated with 400 mg/kg dandelion seed extract, the third treated with 5 mg/kg of cholesterol powder dissolved in oil and the fourth treated with cholesterol and dandelion extract.

Results: It was showed that dandelion seeds extract reduced the weight of the mice. Cholesterol treatment resulted in highly significant increase of liver enzymes activities, total cholesterol, low-density lipoprotein (LDL) and high-density lipoprotein (HDL) of serum besides to pathological changes as steatosis, inflammation, fibrosis and high pathological score in the liver. Dandelion seeds extraction treatment resulted in marked decrease of liver enzymes activities total cholesterol, HDL and LDL of serum, in addition to hepatic tissue improvement with less steatosis, inflammation, fibrosis and lowered pathological score.

Conclusion: Dandelion seeds extract could reduce hypercholesterolemia in swiss albino mice.

© 2022 The Author(s). Published by Elsevier B.V. on behalf of King Saud University. This is an open access article under the CC BY license (<http://creativecommons.org/licenses/by/4.0/>).

1. Introduction

Cholesterol is a molecule with polar head and a non polar side chain called amphipathic. It is found in the cells and blood of all animals which considered the main component of cell membrane and steroid hormones (Adekiya et al., 2018). The increasing of low density lipoprotein cholesterol levels in the plasma leads to metabolic disorder known as hypercholesterolemia (Mu et al., 2017). Elevation of blood cholesterol levels contributes in several diseases as heart attacks, atherosclerosis, kidney failure and steatosis (Hassan et al., 2011). Consumption of high-fat and high-cholesterol food besides to bad lifestyles lead to hypercholesterolemia and also may be to insulin resistance (IR) resulted in dia-

betes mellitus with its complications (Munshi et al., 2014; Han et al., 2018). In humans, high-fat diets commonly induced hypercholesterolemia in addition to physiological disorders as LDL-cholesterol receptors deficiencies. Hypercholesterolemia infinitely affects the liver inducing hazardous effects such as steatosis, fibrosis and portal hypertension (Musial et al., 2013). Chemical drugs were widely used as antihyperlipidemic medicines in markets. Whereas, accumulative studies reported that side effects of lipid-lowering medicines considered a problematic issue (Jiang et al., 2018). For example, it was found that atorvastatin which is a well known treatment caused increasing of the gut microbiota diversity (Khan et al., 2018).

Nowadays, concept of “functional food” are holding a great interest of consumers and scientists such as vegetables, fruits and herbs contain bioactive ingredients (Sakr and Dawood, 2016; Ji et al., 2019). Botanical medicine is a wide range method in the world. Herbs not only used for nutrition purposes but also for medicinal treatments (Shaito et al., 2020). Dandelion (*Taraxacum officinale*) is a famous herb belonged to Asteraceae family located in zones with warm temperature. Dandelion possesses phytochemical and bioactive compounds such as lactones, polysaccha-

* Corresponding author.

E-mail address: delnaggat@ksu.edu.sa (D.M. El-Nagar).

Peer review under responsibility of King Saud University.



Production and hosting by Elsevier

rides, terpenoids and phenolic compounds (Hamza et al., 2020). Additionally, dandelion considered a natural source of minerals as iron, potassium, zinc and calcium besides to fibers and vitamins as B complex and C (Arafa et al., 2010). Dandelion gained a marked interest because of its impacted effects as antioxidant, anti-inflammatory and anti-fibrotic agent (Ouarda et al., 2014; Devaraj, 2016). In folk medicines of India and China dandelion was used to treat respiratory system infections, inflammation, anemia and blood purification (Modaresi and Resalatpour, 2012).

Based on the previous data the present study was designed to investigate the effect of dandelion seeds extract to ameliorate the hypercholesterolemia in the blood and steatosis in the liver induced by cholesterol intake in swiss albino mice.

2. Materials and methods

2.1. Preparation of dandelion seeds extract

Seeds grinded into very fine powder then mixed with methanol solvent (1:10), the mixture left on shaker overnight. The mixture subjected to filtration for the first time, the filtrate kept in the refrigerator and the remain powder mixed with solvent again and left overnight. It subjected to filtration for second time to make sure that at all the components were filtrated. Both the two filtrates were combined and subjected to lyophilization and convert it from liquid to powder.

2.2. Animal study

Forty male mice obtained from King Saud University animal house, weighed 30 ± 5 g, aged 14 weeks, kept in cages and fed on normal commercial diet for 1 week for adaptation. After that mice were divided randomly into 4 groups, 10 mice per each. The 1st group served as untreated control group, the 2nd group treated daily with oral injection of 400 mg/kg of dandelion seeds extract, the 3rd group treated daily with oral injection of 5 mg/kg of cholesterol powder (Sigma) dissolved in Sesame oil and the 4th group received the same dose of 3rd group and treated daily with oral injection of 400 mg/kg of dandelion seeds extract. Experiment was lasted for 4 weeks and all animals were sacrificed at the end of experiment under anesthesia by carbon dioxide flow.

2.3. Weights and liver index

Mice were weighed at the beginning and the end of the experiment to obtain initial and final weights. After sacrificing liver of each mice was weighed and divided on the final body weight multiplied by 100 to get liver index.

2.4. Biochemical analysis

Blood samples were collected by heart puncture and drawn in centrifuge tubes then centrifuged at 3000g. Sera were collected and kept in -20 °C for assays. Sera were subjected to estimation of liver enzymes activities (ALT, AST and ALP), total cholesterol, HDL and LDL using commercial kits (Biosystem-Spain).

2.5. Histopathological analysis and liver pathological score

Mice livers of the all experimental groups were fixed in 10% neutral buffered formalin. Fixed livers dehydrated by ethanol alcohol, cleared by xylene and embedded in wax. Blocks were sectioned at 6 μ m thickness. Sections were dried, rehydrated by ethanol and stained by Hematoxylin and Eosin (Bancroft and Gamble, 2008), other sections stained by Masson's trichrome for

fibrosis detection (Suvik and Effendy, 2012). Pathological score was graded according to (Bedossa et al., 2012). Criteria as following: Ballooning, 0 = normal, 1 = some cells showed enlargement and swelling, 2 = most of cells showed enlargement and swelling; inflammation, 0 = non, $1 \leq 2$ foci, $2 > 2$ foci; fibrosis, 0 = non, 1 = portal/parenchymal, 2 = interlobular, 3 = both; steatosis, 0 = non, 1 = micro-vesicular steatosis, 2 = macro-vesicular steatosis, 3 = both. Examination was carried out on $40\times$ for 10 field.

2.6. Statistical analysis

The data will be expressed as mean \pm SEM (standard error of the mean). Statistical significance of the control and experimental groups will be evaluated by SPSS v.16 software program (SPSS Inc., Chicago, Illinois, USA). Comparison will be done between control and experimental groups by ANOVA, $p \leq 0.05$ will be considered to be significant.

3. Results

3.1. Dandelion seeds extract decreased the final weight

As shown in (Table 1) mice group treated with dandelion seeds extract showed significant decrease compared to the initial weight. Whereas, the group treated with cholesterol revealed insignificant increase of the final weight compared to initial weight. Moreover, the group treated with cholesterol and dandelion seeds extract displayed insignificant decrease of final weight compared to initial weight. Liver index showed no significant change in the experimental groups compared to control group. The results illustrated that dandelion extract could decrease the weight as it used only or with that treated with cholesterol.

3.2. Dandelion seeds extract ameliorated the liver enzymes elevated by cholesterol

Dandelion seeds extract treatment showed no significant change in liver enzymes activities compared to control group. While, cholesterol treatment induced highly significant increase of liver enzymes activities compared to control group. Furthermore, dandelion seeds extract treatment with cholesterol resulted in significant decrease of liver enzymes activities compared to cholesterol treatment only (Table 2).

3.3. Dandelion seeds extract reduced cholesterol levels increased by cholesterol treatment

Mice group treated with dandelion seeds extract revealed no significant change in cholesterol, HDL and LDL levels compared to control group. Additionally, the group treated with cholesterol showed highly significant increase of cholesterol, HDL and LDL levels compared to control group, it was found that LDL level highly elevated compared to HDL. Moreover, the group treated with dandelion seeds extract and cholesterol showed significant

Table 1
Showing the initial weight, final weight and liver index in control and experimental groups.

Groups	Initial weight	Final weight	Liver index
Control	35 ± 0.3	36 ± 0.3	7 ± 0.03
Dandelion	35 ± 0.2	25 ± 0.3^a	7 ± 0.03
Cholesterol	34 ± 0.4	37 ± 0.4	7 ± 0.03
Dandelion + cholesterol	34 ± 0.1	31 ± 0.1	6 ± 0.01

Data = mean \pm SEM.

^a $P \leq 0.05$ significant against initial weight.

Table 2
Showing the liver enzymes activities (U/L) in control and experimental groups.

Groups	ALT	AST	ALP
Control	31 ± 0.8	200 ± 0.3	137 ± 0.3
Dandelion	35 ± 0.4	202 ± 0.3	138 ± 0.3
Cholesterol	70 ± 0.1 ^a	271 ± 0.5 ^a	202 ± 0.5 ^a
Dandelion + cholesterol	38 ± 0.9 ^b	229 ± 0.3 ^{a,b}	148 ± 0.4 ^b

Data = mean ± SEM.

^a P ≤ 0.05 significant against control group.

^b P ≤ 0.05 significant against cholesterol group.

decrease of total cholesterol level, whereas HDL revealed insignificant increased level and LDL showed significant decreased level compared to cholesterol treated group (Table 3).

3.4. Dandelion seeds extract reduced steatosis, inflammation and fibrosis cholesterol- induced

Control and dandelion seeds extract mice liver showed normal hepatic structure without any pathological signs (Fig. 1A and B). Mice liver treated with cholesterol posted severe pathological changes represented by dilatation, congestion of vein that sur-

Table 3
Displaying cholesterol levels, HDL and LDL (mg/dl) of experimental groups.

Groups	Cholesterol	HDL	LDL
Control	85 ± 0.5	62 ± 0.4	24 ± 0.2
Dandelion	89 ± 0.9	61 ± 0.5	22 ± 0.6
Cholesterol	170 ± 0.1 ^a	82 ± 0.2 ^a	112 ± 0.3 ^a
Dandelion + cholesterol	142 ± 0.5 ^{a,b}	85 ± 0.5 ^a	80 ± 0.3 ^{a,b}

Data = mean ± SEM.

^aP ≤ 0.05 significant against control group.

^bP ≤ 0.05 significant against cholesterol group.

rounded by infiltrative cells and pyknotic nuclei of hepatocytes besides to marked micro and macro-vesicular steatosis (Fig. 1C). Hepatic tissue of mice treated with dandelion seeds extract and cholesterol displayed marked improvement manifested by healthy vein and hepatocytes and less micro-vesicular steatosis (Fig. 1D).

Control and dandelion seeds extract mice liver Masson's trichrome stained revealed no fibrosis (Fig. 2A and B). Whereas, liver mice treated with cholesterol posted precipitation of collagenous fibers with inflammatory cells (Fig. 2C). Furthermore, mice liver treated with dandelion seeds extract and cholesterol indicated less fibrotic foci with a few number of inflammatory cells (Fig. 2D).

3.5. Dandelion seeds extract lowered pathological score increased due to cholesterol treatment

Control and dandelion seeds extract mice liver scored 0 due to no pathological alterations. liver mice treated with cholesterol showed high pathological grade scored 10 attributed to ballooning of the most hepatocytes, heavy incidence of inflammation, portal and interlobular fibrosis with large areas and massive incidence of micro and macro-vesicular steatosis. Additionally, mice liver treated with dandelion seeds extract and cholesterol displayed lowered pathological grade scored 4 referring to reduction of pathological signs (Table 4).

4. Discussion

The present study findings indicated that cholesterol treatment resulted in insignificant increase of the final weight that coincided with Choi et al., results that high-cholesterol diet leading to hypercholesterolemia resulted in insignificant increase of the final weight compared to initial weight (Choi et al., 2010). Additionally, the present work referred to the effect of dandelion seeds extract

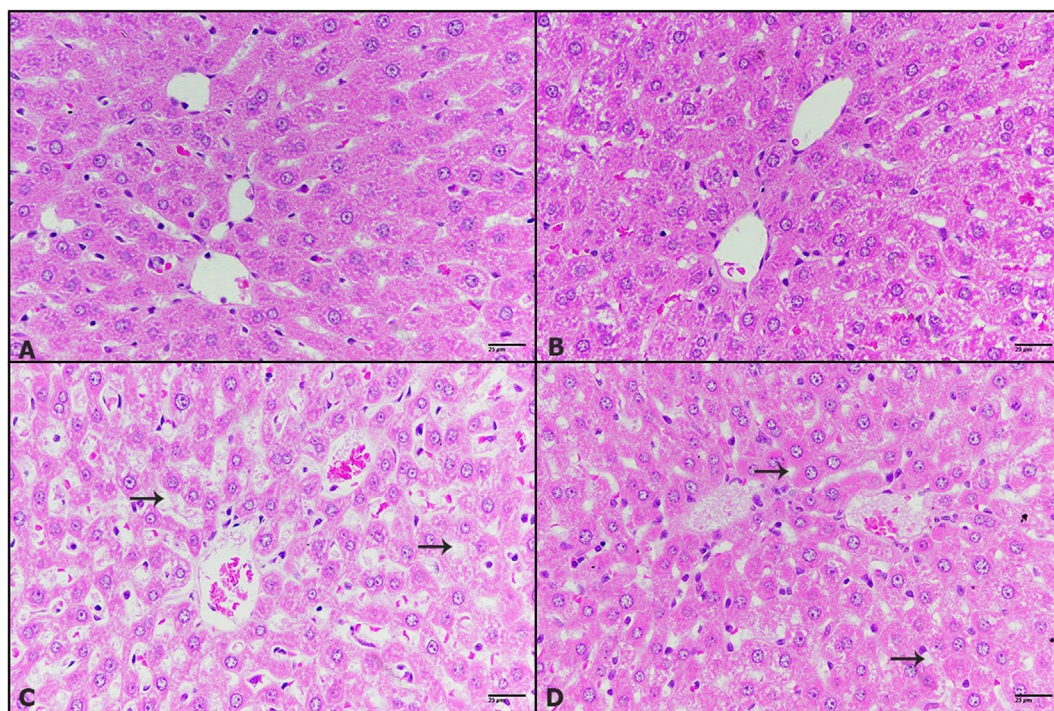


Fig. 1. The effect of dandelion seeds extract on pathological changes cholesterol-induced in liver. Photomicrographs of mice liver (A) control liver showing normal hepatic structure (B) treated with 400 mg/kg dandelion seeds extract showing normal structure (C) treated with 5 mg/kg of cholesterol displaying dilated and congested vein, steatosis (black arrows), pyknotic nucleus (green arrow) (D) treated with 5 mg/kg cholesterol and 400 mg/kg dandelion seeds extract posting small micro-vesicular steatosis (black arrow). (H&E-400×).

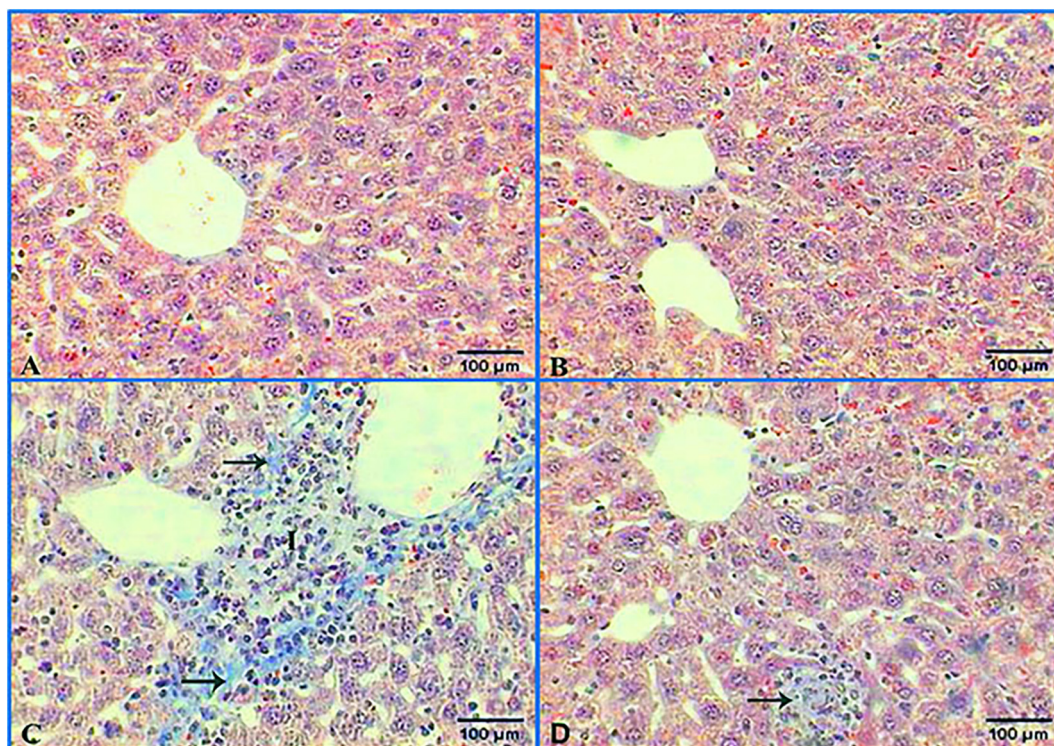


Fig. 2. The effect of dandelion seeds extract to reduce the fibrosis and inflammation cholesterol-induced in liver. Photomicrographs of mice liver (A) control liver showing no fibrosis (B) treated with 400 mg/kg dandelion seeds extract showing no fibrosis (C) treated with 5 mg/kg of cholesterol displaying accumulation of collagenous fibers (black arrows), inflammatory cells (I) (D) treated with 5 mg/kg cholesterol and 400 mg/kg dandelion seeds extract posting small foci of fibrosis with a few number of inflammatory cells (black arrow). (M.Tr-400×).

Table 4
Liver pathological scoring system in experimental groups.

Groups	Ballooning	Inflammation	Fibrosis	Steatosis	Total
Control	0	0	0	0	0
Dandelion	0	0	0	0	0
Cholesterol	2	2	3	3	10
Dandelion + cholesterol	1	1	1	1	4

to decrease the weight of mice without or with cholesterol treatment.

High-fat and high-cholesterol diets induced hypercholesterolemia resulted in elevation of liver biomarkers. Furthermore, treatment with high-cholesterol diet resulted in highly increase of ALT, AST and ALP activity levels in the blood plasma that considered a marked sign for hepatic injury (Wang et al., 2010; Adekiya et al., 2018). The current study declared that cholesterol treatment highly raised the liver enzymes activities that cytosolic enzymes as ALT, AST and ALP drawn in the circulatory blood due to damage of hepatocytes lead to elevation of enzymes activities levels in the plasma. On the other hand, several studies indicated the effect of dandelion extract to reduce the liver biomarkers elevated by CCL₄ (Al-malki et al., 2013; Dawood et al., 2014), and also by heavy metals as lead (Ouarda et al., 2014). The present study referred to the regulated effect of dandelion seeds extract to decrease the liver enzymes activities that raised due to cholesterol treatment.

High-cholesterol diets lead to hypercholesterolemia considered the main factor to raise the total cholesterol, HDL and LDL in the plasma (Choi et al., 2010; Sakr and Dawood, 2016; Paim et al., 2017). Accordingly, treatment with cholesterol in oil induced highly raising of total cholesterol level in the serum. Other studies posted that dandelion extracts of leaves and roots positively reduced the cholesterol level in rabbit fed on cholesterol diet (Choi et al., 2010) and also in mice fed an atherogenic diets (Kim

et al., 2014). Interestingly, it was found that elevation of HDL correlated with lowering of LDL which considered an essential role in lipid metabolism by transferring cholesterol ester from HDL to LDL (Kaabia et al., 2018). The present work displayed that dandelion seeds extract have significantly decreased the level of total cholesterol, HDL and LDL in the serum that increased due to cholesterol treatment, which agreed with Choi et al. who declared that dandelion extract lowered the lipid profiles in rabbits fed on cholesterol and then protect against atherosclerosis (Choi et al., 2010). Recent study showed that dandelion fractions could improve the lipid profile to decrease TG and total cholesterol. It was suggested to reduce the production of cyclooxygenase and cause vasodilation and then modify the blood pressure and heart rate (Majewski et al., 2020). Meanwhile, more recent study displayed that aqueous extract of dandelion actually lowered the lipid profile that might be due to the increasing of the activation of adenosine monophosphate leading to decreasing of lipids accumulation in the liver (Ikram et al., 2021).

The liver is the main organ considered with the maintenance of cholesterol and affected extremely by increasing cholesterol. The present work posted marked pathological changes in the liver due to cholesterol treatment as severe steatosis, inflammation and also fibrosis with raised pathological scoring system as a result of hazardous signs. These findings accompanied with other previous studies declared that high-cholesterol diets resulted in accu-

mulation of lipid droplets in the hepatocytes (Paim et al., 2017) and inflammation (Sadeghipour et al., 2014; Sakr and Dawood, 2016). Moreover, the current results showed decreasing of steatosis, inflammation and fibrosis leading to highly decrease of pathological score in liver as dandelion seeds extract combined with cholesterol treatment.

5. Conclusion

The present work postulated that hypercholesterolemia raised the liver enzymes activities, total cholesterol, LDL and HDL. Additionally, hypercholesterolemia caused steatosis, inflammation and fibrosis in the liver. Dandelion seeds extract could reduce the pathophysiological parameters that elevated by cholesterol and also ameliorated steatosis, inflammation and fibrosis.

Declaration of Competing Interest

The authors declare that they have no known competing financial interests or personal relationships that could have appeared to influence the work reported in this paper.

Acknowledgement

This article is funded by King Saud University, Riyadh, Saudi Arabia Researchers Support Project (RSP-2021/214).

Contribution

Authors contributed in all steps of the search.

References

- Adekiya, T.A., Shodehinde, S.A., Aruleba, R.T., 2018. Anti-hypercholesterolemic effect of unripe *Musa paradisiaca* products on hypercholesterolemia-induced rats. *J. Appl. Pharm. Sci.* 8 (10), 90–97. <https://doi.org/10.7324/JAPS.2018.81012>.
- Al-malki, A.L., Abo-golayel, M.K., Abo-elnaga, G., 2013. Hepatoprotective effect of dandelion (*Taraxacum officinale*) against induced chronic liver cirrhosis. *J. Med. Plants Res.* 7 (20), 1494–1505. <https://doi.org/10.5897/JMPR12.11116>.
- Arafa, R., El-Said, M., Abdel-Rahman, M., Abdel-Megied, A., 2010. Carbon tetrachloride- induce hepatotoxicity in rats: The potential effect of bread supplemented with dandelion(*Taraxacum Officinale*) on the nutritional status. *Agricultura, Maribor University, Slovenia* 7, 23–32.
- Bancroft, J.D., Gamble, M., 2008. Theory and practice of histological techniques. Elsevier health sciences.
- Bedossa, P., Poitou, C., Veyrie, N., Bouillot, J.L., Basdevant, A., Paradis, V., Tordjman, J., Clement, K., 2012. Histopathological algorithm and scoring system for evaluation of liver lesions in morbidly obese patients. *Hepatology* 56 (5), 1751–1759. <https://doi.org/10.1002/hep.25889>.
- Choi, U.-K., Lee, O.-H., Yim, J.H., Cho, C.-W., Rhee, Y.K., Lim, S.-I., Kim, Y.-C., 2010. Hypolipidemic and antioxidant effects of dandelion (*Taraxacum officinale*) root and leaf on cholesterol-fed rabbits. *Int. J. Mol. Sci.* 11 (1), 67–78. <https://doi.org/10.3390/ijms11010067>.
- Dawood, A., Muhammad, G., M., S.A., Habiba, N., Hina, G., Saira, A., 2014. Protective action of *Taraxacum officinale* on CCl4 induced hepatotoxicity in rats. *Afr. J. Pharm. Pharmacol.* 8 (30), 775–780.
- Devaraj, E., 2016. Hepatoprotective properties of Dandelion: Recent update. *J. Appl. Pharm. Sci.* 6 (4), 202–205. <https://doi.org/10.7324/JAPS.2016.60429>.
- Hamza, A.A., Mohamed, M.G., Lashin, F.M., Amin, A., 2020. Dandelion prevents liver fibrosis, inflammatory response, and oxidative stress in rats. *J. Basic Appl. Zool.* 81 (1), 43–56. <https://doi.org/10.1186/s41936-020-00177-9>.
- Han, Q., Yeung, S.C., Ip, M.S.M., Mak, J.C.W., 2018. Dysregulation of cardiac lipid parameters in model. *Lipids Health Dis.* 17, 1–10.
- Hassan, S., El-Twab, S.A., Hetta, M., Mahmoud, B., 2011. Improvement of lipid profile and antioxidant of hypercholesterolemic albino rats by polysaccharides extracted from the green alga *Ulva lactuca* Linnaeus. *Saudi J. Biol. Sci.* 18 (4), 333–340.
- Ikram, T., Iffriqya, M., Saoussane, L., 2021. Hypolipidemic and cardioprotective effects of *Taraxacum officinale* aqueous extract in obese rats. *Veterinarska Stanica* 52 (4), 405–412.
- Ji, X., Shi, S., Liu, B., Shan, M., Tang, D., Zhang, W., Zhang, Y., Zhang, L., Zhang, H., Lu, C., Wang, Y., 2019. Bioactive compounds from herbal medicines to manage dyslipidemia. *Biomed. Pharmacother.* 118, (July). <https://doi.org/10.1016/j.biopha.2019.109338>.
- Jiang, Y., Fu, C., Liu, G., Guo, J., Su, Z., 2018. Cholesterol-lowering effects and potential mechanisms of chitoooligosaccharide capsules in hyperlipidemic rats. *Food Nutr. Res.* 62. <https://doi.org/10.29179/fnr.v62.1446>.
- Kaabia, Z., Poirier, J., Moughaizel, M., Aguesse, A., Billon-Crossouard, S., Fall, F., Durand, M., Dagher, E., Krempf, M., Croyal, M., 2018. Plasma lipidomic analysis reveals strong similarities between lipid fingerprints in human, hamster and mouse compared to other animal species. *Sci. Rep.* 8 (1), 15893. <https://doi.org/10.1038/s41598-018-34329-3>.
- Khan, T.J., Ahmed, Y.M., Zamzami, M.A., Mohamed, S.A., Khan, I., Baothman, O.A.S., Mehanna, M.G., Yasir, M., 2018. Effect of atorvastatin on the gut microbiota of high fat diet-induced hypercholesterolemic rats. *Sci. Rep.* 8 (1), 662. <https://doi.org/10.1038/s41598-017-19013-2>.
- Kim, J.J., Park, C.M., Kim, M.J., Cho, C.W., Song, Y.S., 2014. Hypolipidemic effect of dandelion (*Taraxacum officinale*) extracts via fecal lipid excretion in C57BL/6 mice fed an atherogenic diet. *Food Sci. Biotechnol.* 23 (3), 841–847. <https://doi.org/10.1007/s10068-014-0113-5>.
- Majewski, M., Lis, B., Juškiewicz, J., Ognik, K., Borkowska-Sztachañska, M., Jedrejek, D., Stochmal, A., Olas, B., 2020. Phenolic fractions from dandelion leaves and petals as modulators of the antioxidant status and lipid profile in an in vivo study. *Antioxidants* 9 (2), 1–13. <https://doi.org/10.3390/antiox9020131>.
- Modaresi, M., Resalatpour, N., 2012. The effect of *Taraxacum officinale* hydroalcoholic extract on blood cells in mice. *Adv. Hematol.* 2012, 653412. <https://doi.org/10.1155/2012/653412>.
- Mu, F., Rich-Edwards, J., Rimm, E.B., Spiegelman, D., Forman, J.P., Missmer, S.A., 2017. Epidemiology / population association between endometriosis and hypercholesterolemia or hypertension. *Hypertension* 70 (1), 59–65. <https://doi.org/10.1161/HYPERTENSIONAHA.117.09056>.
- Munshi, R., Kalekar, S., Rane, B., 2014. Development of an experimental diet model in rats to study hyperlipidemia and insulin resistance, markers for coronary heart disease. *Indian J. Pharmacol.* 46 (3), 270–276. <https://doi.org/10.4103/0253-7613.132156>.
- Musial, D.C., Cristina, T., Becker, A., Isolani, A.P., Bracht, L., 2013. Acta Scientiarum Hypercholesterolemia and hepatic steatosis in mice fed on low-cost high-fat diet. *Acta Scient.* 35 (1), 23–27. <https://doi.org/10.4025/actascihealthsci.v35i1.10871>.
- Ouarda, M., Berredjem, R., Abdennour, C., Boulakoud, M.S., Khelili, K., 2014. Protective effect of *Taraxacum officinale* against oxidative damage induced by lead (Pb) in rats exposed to contaminated diet. *Adv. Environ. Biol.* 8 (10), 519–525.
- Paim, R.T.T., Benjamin, S.R., Rondina, D., Marques, M.M.M., De Araújo Viana, D., Da Costa Gonzaga, M.L., Vieira, Í.G.P., Mendes, F.N.P., Rodrigues, P.A.S., Guedes, M.I. F., 2017. Antihypercholesterolemic effects of fruit aqueous extract of *Copernicia prunifera* (Miller) H. E. Moore in Mice diet-induced hypercholesterolemia. *Evid.-Based Complement. Altern. Med.* 2017, 1–15. <https://doi.org/10.1155/2017/6376173>.
- Sadeghipour, A., Eidi, M., Ilchizadeh KavGANI, A., Ghahramani, R., Shahabzadeh, S., Anissian, A., 2014. Lipid lowering effect of punica granatum L. Peel in high lipid diet fed male rats. *Evid.-Based Complement. Altern. Med.* 2014, 1–5. <https://doi.org/10.1155/2014/432650>.
- Sakr, S.S., Dawood, S.A.A., 2016. Hypocholesterolemic effect of pomegranate's peel (water extract) supplemented yoghurt in hypercholesterolemic rats. *Indian J. Dairy Sci.* 68 (1), 14–19.
- Shaito, A., Thuan, D.T.B., Phu, H.T., Nguyen, T.H.D., Hasan, H., Halabi, S., Abdelhady, S., Nasrallah, G.K., Eid, A.H., Pintus, G., 2020. Herbal medicine for cardiovascular diseases: efficacy, mechanisms, and safety. *Front. Pharmacol.* 11, 1–32. <https://doi.org/10.3389/fphar.2020.00422>.
- Suvik, A., Effendy, A.W.M., 2012. The use of modified Masson's trichrome staining in collagen evaluation in wound healing study. *Mal J Vet Res* 3 (1), 39–47.
- Wang, Y.-M., Zhang, B., Xue, Y., Li, Z.-J., Wang, J.-F., Xue, C.-H., Yanagita, T., 2010. The mechanism of dietary cholesterol effects on lipids metabolism in rats. *Lipids Health Dis.* 9, 4. <https://doi.org/10.1186/1476-511X-9-4>.